

Case Report

Salmonella Septic Arthritis in A Patient with A Hip Implant:
A Case Report

I-fan Lo, Hao-chiun Chang*

Department of orthopedics, MacKay Memorial Hospital, Taiwan



ARTICLE INFO

Article history:

Received 4 August 2017

Received in revised form

15 January 2018

Accepted 29 January 2018

Available online 16 March 2018

Keywords:

Avascular necrosis,
Immunosuppression,
Non-typhi salmonella

SUMMARY

Joint infections due to non-typhi *Salmonella* are rare, and usually associated with sickle cell anemia or other immunosuppressive disorders. An 80-year-old female, with a recent history of lung adenocarcinoma and a 20 year history of rheumatoid arthritis with steroid use, presented with hip pain. Her right hip had 3 screws due to a femoral neck fracture 5 years previously, and she reported suffering from intermittent right hip pain for the previous 3 years. Patrick's test was positive and X-rays showed rapid progression of femoral head collapse and screw penetration within 3 weeks, suggesting hip infection. We removed the implant, performed sequestrectomy of the femoral head, and inserted a cement spacer with debridement. We administered antibiotics after surgery to control hip sepsis, based on *Salmonella*-positive cultures. The patient ultimately died of sepsis. This case illustrates successful management of hip sepsis requires prompt identification of infection, surgical intervention, and administration of appropriate systemic antibiotics. When a patient presents with musculoskeletal discomfort, the clinician should perform thorough examinations as soon as possible, especially of the patient is immunodeficient. Copyright © 2018, Taiwan Society of Geriatric Emergency & Critical Care Medicine. Published by Elsevier Taiwan LLC. This is an open access article under the CC BY-NC-ND license (<http://creativecommons.org/licenses/by-nc-nd/4.0/>).

1. Introduction

Ingestion of contaminated food products is a common cause of non-typhi *Salmonella* (NTS) infection, but most cases only suffer from gastroenteritis with self-limited symptoms that can be managed with supportive treatment. Antibiotic treatment is rarely indicated.

NTS only rarely causes musculoskeletal infections, and this is most common in individuals with sickle cell anemia or other hemoglobinopathies, those with immunosuppression, and carriers of chronic salmonella or NTS infections.

An NTS musculoskeletal infection is a rare cause of osteomyelitis, and accounts for only approximately 0.45% of all types of osteomyelitis.^{1,2} Septic arthritis due to *Salmonella* usually arises from a hematogenous infection, and the hip joint is the most frequently affected bone.^{3,4} However, periprosthetic joint infection (PJI) caused by *Salmonella* is very rare, and only 20 such patients have been described in the literature.⁵ We present a rare case who had septic arthritis of the hip caused by NTS.

2. Case report

An 80 year-old female presented to our clinic. She was diagnosed with lung adenocarcinoma (cT4N0M0, stage IIIA) 5 years previously, and completed treatment with Iressa. She also had rheumatoid arthritis and received ongoing treatment with a steroid, sulfasalazine, and leflunomide for more than 20 years. She received right hip internal fixation with 3 cannulated screws due to Garden type I femoral neck fracture about 5 years previously, while being treated for lung cancer. However, she reported intermittent right hip pain during the previous 3 years, and was given non-steroidal anti-inflammatory agents for pain control, under the assumption of right hip osteoarthritis (OA). Here records indicated no fever at the recurrent follow-ups in the outpatient clinic. She was admitted to our emergency department due to severe right hip pain one week before the currently described admission, and was discharged with the same diagnosis.

Seven days after this discharge, she was sent to our emergency department again because of conscious drowsiness (E4M5V2 on the Glasgow coma scale), shortness of breath with desaturation ($SpO_2 = 84\%$), and a fever of 38.1 °C. A physical examination indicated a positive Murphy sign and a positive Patrick's test. Computed tomography (CT) of the brain showed no obvious intracranial

* Corresponding author. MacKay Memorial Hospital, Department of orthopedics, No.45, Minsheng Rd., Tamsui Dist., New Taipei City, Taiwan.

E-mail address: changhaochiun@gmail.com (Hao-chiun Chang).

hemorrhage or infarction, but an abdominal CT revealed acute cholecystitis. The blood exam indicated an elevated CRP (24.21 mg/dL) and a normal white blood cell count (7900/ μ L), but with a left shift (segmented neutrophils: 87%, band cells: 6%, myelocytes: 3%). We suspected sepsis due to an intra-abdominal infection with right hip osteoarthritis.

After admission, she was given flumarin (1 g intravenous each 8 h). The blood and stool cultures both indicated a *Salmonella* group D infection. Her consciousness improved following antibiotic treatment, and she reported relief from the abdominal pain but persistent right hip pain. Due to an intermittent fever, we shifted the antibiotic to ceftiofime (2 g intravenous each 12 h). We also consulted an orthopedic surgeon because of the persistent right hip pain and bacteremia. X-rays of the right hip showed right femoral head collapse with penetration of the screws, and a nearly dislocated hip joint, with rapid progression during 3 weeks (Fig. 1). An osteomyelitis scan indicated septic arthritis over the right hip (Fig. 2).

Thus, we removed the implant, performed sequestrectomy of the femoral head, and then inserted a vancomycin-containing cement spacer (Fig. 3). A pus culture from the hip joint indicated *Salmonella* group D infection at the first operation, but a pus culture following debridement was negative. One month later, the patient developed pneumonia (*Acinetobacter baumannii*) and a urinary tract infection (*Candida albicans*). She expired due to sepsis 40 days after the hip surgery.

3. Discussion

Salmonella is a genus of Gram-negative bacilli, and one of the three main causes of enteric fever. Some uncommon human pathogens, such as *S. panama*, *S. virchow*, and *S. arizonae*, are rare causes of infections following direct or indirect contact with reptiles, ingestion of snake-based products (such as meat), and certain traditional medical preparations.^{6,7}

Most NTS infections manifest as common gastroenteritis and are self-limited with management by supportive treatment. However, immunodeficient patients may have poorly functioning reticulo-endothelial systems, and an increased risk of systematic infection. Thus, patients with poor immune systems should avoid intake of raw food, snake-based products, and questionable medical preparations.

Salmonella infection of the bones and joints is rare, accounting for only 0.8% of all *Salmonella* infections and 0.45% of all types of

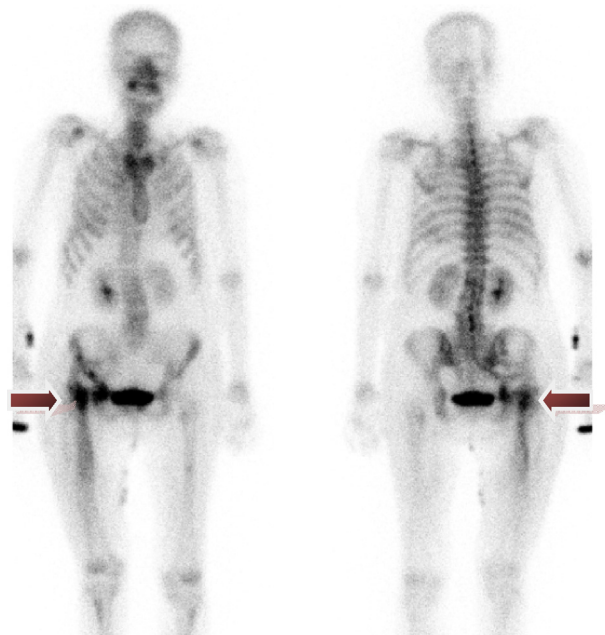


Fig. 2. Bone scan revealed right hip septic arthritis, both AP and PA view indicated the same lesion site (arrow head).

osteomyelitis.⁸ Septic arthritis is a rare consequence of *Salmonella* bacteremia, and is an even more rare cause of joint infection in adults.⁹ Any disease or condition that compromises the immune system,^{10–12} including sickle cell disease, chronic alcoholism, chronic lymphocytic leukemia, rheumatoid arthritis,¹³ systemic lupus erythematosus,¹⁴ neoplastic disease, long-term steroid intake,¹⁵ age greater than 80 years,¹⁶ and possibly AIDS, may increase the risk of *Salmonella* musculoskeletal infection. It is noteworthy that our patient was 80 years-old and had rheumatoid arthritis for which she was receiving ongoing steroid treatment.

Hematogenous spread is probably the most frequent cause of *Salmonella* septic arthritis. Bacteremia occurs in less than 5% of patients with gastrointestinal tract salmonellosis, and is more likely to occur in immunocompromised patients.¹⁷ It is likely that our case developed bacteremia following a gastrointestinal tract infection. In particular, bacteria might have seeded from GI tract to the aortic valve, and then to the osteonecrotic hip. A previous report indicated

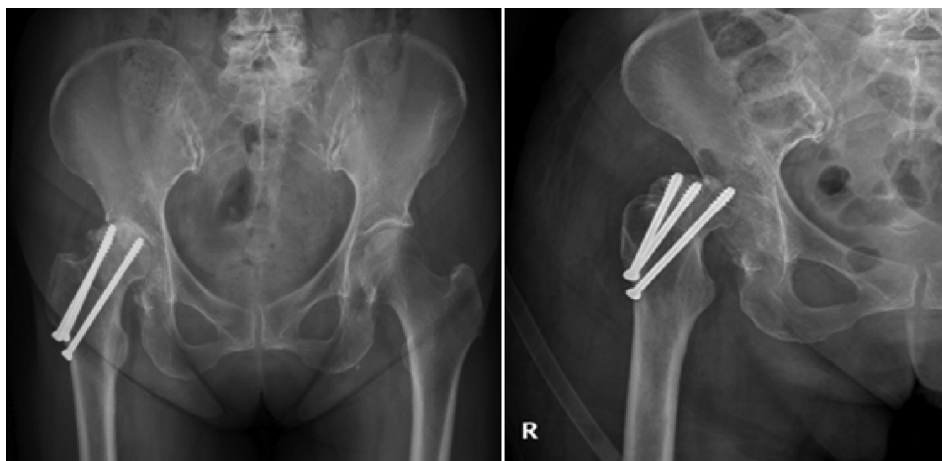


Fig. 1. Right hip X ray showed rapid collapse of femur head, with subluxation of hip joint in 3 weeks after admission.

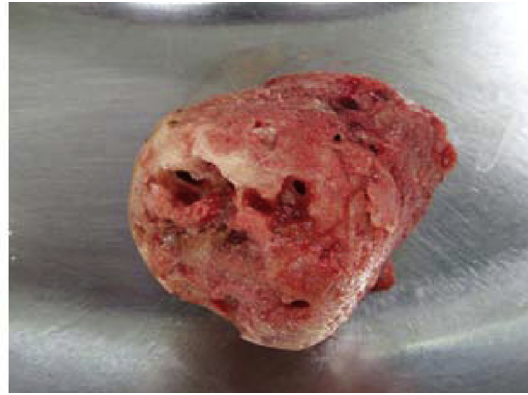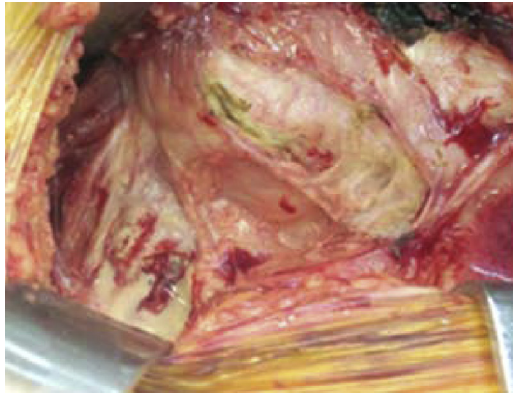


Fig. 3. Removal implant, sequestrectomy of femoral head was done, with purulent joint fluid noted.

that *Salmonella* usually produces monoarticular arthritis, and the hip is the most frequently affected joint.¹⁴ A common predisposing articular factor for *Salmonella* septic arthritis is avascular necrosis, which was also present in our patient.

The novelties of this case are that the patient had rheumatoid arthritis, a history of trauma in the right hip, and intermittent right hip pain, all as a result of a single underlying disease—septic arthritis. There are fewer than 20 reports in the literature of patients with NTS hip infections who have hip implants.

It may be hypothesized that the prolonged use of steroids by our case led to femoral head necrosis, screw penetration, and hematoma formation, followed by pathogen invasion of the hip joint. Another hypothesis is that a micro-trauma of right hip led to hematoma formation, followed by bacterial seeding, and then septic arthritis and head collapse.

Early diagnosis of septic hip arthritis is essential, but the symptoms are typically nonspecific, so early diagnosis is frequently impossible.¹⁸ It is also important to clearly distinguish septic hip arthritis from osteoarthritis, gout, avascular necrosis of the femoral head, synovitis, and other infections that are associated with similar clinical features. Our patient experienced hip pain that increased during range-of-motion exercises, but due to her immunocompromised status and lack of fever, the clinicians did not initially consider the possibility of a septic hip. However, the rapid progression of head collapse indicated an active infection. In such cases, a septic hip should be considered first in the differential diagnosis. In general, immunodeficient patients with painful joints should be closely followed if symptoms persist.

The erythrocyte sedimentation rate (ESR) and C-reactive protein (CRP) are usually elevated occur during infections, but white blood cell levels can vary, especially in patients with chronic infections.^{13,15} Chronic immunosuppression due to prolonged steroid therapy can depress the humoral immune response, may reduce symptoms and signs of infection, and can alter the Widal test titer.¹⁹ As soon as septic arthritis is suspected, joint fluid cultures must be obtained using CT-guided aspiration or arthrotomy, and blood cultures should be examined. The fluid of an infected joint is usually purulent, as in our patient (Fig. 3).^{20,21} Cultures from other samples, such as urine or catheter tips, might also be useful. The joint fluid, blood, and stool cultures of our patient were all positive for *Salmonella*. Thus, a more complete initial analysis at the outpatient clinic may lead to earlier diagnosis and treatment of the systemic infection.

The successful treatment of osteoarticular *Salmonella* infection usually requires extensive and sometimes multiple debridements, in addition to prolonged antibiotic therapy,²² typically for at least 4–6 weeks.^{23,24} Joint drainage can be performed using aspiration or

arthroscopy. After infection control, some reports strongly recommend a 2-stage total hip arthroplasty to treat sequelae and to assure recovery and full functional restoration of the joint.²³

4. Conclusion

Salmonella septic arthritis of the hip is rare and difficult-to-treat condition. Early diagnosis and surgical intervention with administration of appropriate systemic antibiotics play pivotal roles in successful management. Although infections can predispose a patient to avascular necrosis, our patient was on long-term steroid therapy for rheumatoid arthritis, so differentiation of avascular necrosis of the femur head from septic hip is important. We also note that *Salmonella* infections are much more common in Taiwan than in the United States or Europe, presumably due to the lower use of antacid medications in Taiwan.²⁵ Thus, when a patient presents with musculoskeletal discomfort (back or joint pain), the clinician should perform a thorough examination and consider NTS in the differential diagnosis, especially if the patient is immunodeficient and from Taiwan.

Conflicts of interest

All authors declare no competing financial and non-financial interests.

References

- Bennett JE, Dolin R, Blaser MJ. *Mandell, Douglas, and Bennett's Principles and Practice of Infectious Diseases*. Elsevier Health Sciences; 2014.
- Agnihotri N, Dhingra MS, Gautam V, et al. *Salmonella typhi* septic arthritis of hip—a case report. *Jpn J Infect Dis*. 2005;58:29–30.
- Hook E, Campbell C, Weens H, et al. *Salmonella* osteomyelitis in patients with sickle-cell anemia. *N Engl J Med*. 1957;257:403–407.
- Spencer J, Cattermole G, Andrade T, et al. *Salmonella* osteoarticular infection without predisposing factors. *J R Soc Med*. 1999;92:363.
- Torre Basilio de la, Tena Daniel, Arias Marta, et al. Recurrent prosthetic joint infection due to *Salmonella* enteritidis: case report and literature review. *Eur J Orthop Surg Traumatol*. 2012;22(Suppl 1):S89–S97.
- Cobos JA, Calhoun JH, Mader JT. *Salmonella typhi* osteomyelitis in a nonsickle cell patient a case report. *Clin Orthop Relat Res*. 1993;288:277–281.
- van Cappelle HG, Veenendaal D, de Vogel PL. *Salmonella* Panama osteomyelitis in an otherwise healthy patient. *Clin Orthop Relat Res*. 1995;321:235–238.
- Gondusky JS, Gondusky CJ, Helmers SW. *Salmonella* osteomyelitis in new-onset diabetes mellitus. *Orthopedics*. 2009;32(9).
- Cohen JI, Bartlett JA, Corey GR. Extra-intestinal manifestations of salmonella infections. *Medicine*. 1987;66:349–388.
- Ramos J, Garcia-Corbeira P, Aguado J, et al. Osteoarticular infections by salmonella non-typhi. *Enferm Infecc Microbiol Clin*. 1994;13:406–410.
- Ramos JM, Núñez A, Cuenca M, et al. Focal infections due to non-typhi salmonella in patients with aids: report of 10 cases and review. *Clin Infect Dis*. 1997;25:690–697.

12. Saraux A, Taelman H, Blanche P, et al. Hiv infection as a risk factor for septic arthritis. *Rheumatology*. 1997;36:333–337.
13. Yeargan SA, Perry JJ, Kane TJ, et al. Hematogenous septic arthritis of the adult hip. *Orthopedics*. 2003;26:771–776.
14. Huang JL, Hung JJ, Wu KC, et al. Septic arthritis in patients with systemic lupus erythematosus: Salmonella and nonsalmonella infections compared. *Semin Arthritis Rheum*. 2006;61–67.
15. Milgram JW, Rana NA. Resection arthroplasty for septic arthritis of the hip in ambulatory and nonambulatory adult patients. *Clin Orthop Relat Res*. 1991;272:181–191.
16. Kaandorp CJ, Schaardenburg DV, Krijnen P, et al. Risk factors for septic arthritis in patients with joint disease. *Arthritis Rheum*. 1995;38:1819–1825.
17. Kung YC, Hsieh WY, Sun S, et al. Hemoptysis from a ruptured mycotic aneurysm caused by salmonella. *Int J Gerontol*. 2009;3(2):133–136.
18. Bulmer J. Septic arthritis of the hip in adults. *J Bone Joint Surg Br*. 1966;48:289–298.
19. Organization WH. *Guidelines on Standard Operating Procedures for Microbiology*. WHO; 2005.
20. Samra Y, Shaked Y, Maier MK. Nontyphoid salmonellosis in patients with total hip replacement: report of four cases and review of the literature. *Rev Infect Dis*. 1986;8:978–983.
21. Day L, Qayyum Q, Kauffman C. Salmonella prosthetic joint septic arthritis. *Clin Microbiol Infect*. 2002;8:427–430.
22. Schneider L, Ehlinger M, Stanchina C, et al. Salmonella enterica subsp. *Arizonae* bone and joints sepsis. A case report and literature review. *Orthop Traumatol Surg Res*. 2009;95:237–242.
23. Cheung W, Luk KD. Pyogenic spondylitis. *Int Orthop*. 2012;36:397–404.
24. Compain C, Michou L, Orcel P, et al. Septic arthritis of the hip with psoas abscess caused by non-typhi salmonella infection in an immunocompetent patient. *Joint Bone Spine*. 2008;75:67–925.
25. Kao CJ, Chang WH, Choi WM. Salmonella aortic aneurysm: a patient with non-specific type of low-back and abdominal pain. *Int J Gerontol*. 2007;1(3):134–137.