



# International Journal of Gerontology

journal homepage: <http://www.sgecm.org.tw/ijge/>

## Case Report

# Severe Vitamin B12 Deficiency in an Elderly Woman Underwent Total Gastrectomy and Total Esophagectomy with Ileum-Right Colon Reconstruction

Ying-Chi Chiang<sup>a</sup>, Yen-Po Chen<sup>a,b,c</sup>, Pei-Tzu Chang<sup>d</sup>, Yu-Ru Yang<sup>d</sup>, Ming-Jen Chen<sup>a,c,d\*</sup>

<sup>a</sup> Division of Gastroenterology and Hepatology, Department of Internal Medicine, MacKay Memorial Hospital, Taipei, Taiwan, <sup>b</sup> Department of Nursing, MacKay Junior College of Medicine, Nursing and Management, Taipei, Taiwan, <sup>c</sup> Department of Medicine, MacKay Medical College, New Taipei, Taiwan, <sup>d</sup> Medical Nutrition Center, MacKay Memorial Hospital, Taipei, Taiwan

## ARTICLE INFO

Accepted 22 January 2024

### Keywords:

vitamin B12,  
aged,  
gastrectomy,  
anemia,  
nutrients

## SUMMARY

Vitamin B12 deficiency-associated symptoms include fatigue, neurological symptoms such as tingling sensations, memory difficulties, and anemia. Certain populations face an elevated risk of vitamin B12 deficiency. For instance, vegetarians are susceptible to vitamin B12 deficiency due to the absence of animal-derived foods in their diet. Similarly, older adults and individuals with gastrointestinal disorders like Crohn's disease or celiac disease are more likely to experience malabsorption issues, predisposing them to an increased risk of vitamin B12 deficiency. Furthermore, individuals with a history of total gastrectomy are exceptionally predisposed to developing vitamin B12 deficiency. This case report presents the case of an 80-year-old woman who underwent total gastrectomy and esophagectomy with ileum-right colon reconstruction and severe vitamin B12 deficiency. She exhibited general weakness and rapidly progressing cognitive impairment. We also reviewed the literature to provide current insights into the symptoms, risk factors, and treatments.

Copyright © 2024, Taiwan Society of Geriatric Emergency &amp; Critical Care Medicine.

## 1. Introduction

The modern world has made significant progress in nutritional advancements, improving access to diverse and fortified foods and reducing the prevalence of vitamin B12 deficiency. Vitamin B12, also known as cobalamin, is a vital nutrient crucial in various physiological processes, including DNA synthesis, nerve function, and red blood cell formation.<sup>1</sup>

Vitamin B12 deficiency-associated symptoms include fatigue, weakness, and anemia; neurological symptoms are also common and may manifest as tingling sensations, memory difficulties, trouble concentrating, and balance issues.<sup>2,3</sup> Certain populations face an elevated risk of vitamin B12 deficiency. Vegetarians, for instance, are susceptible due to the absence of animal-derived foods in their diets, which are primary sources of vitamin B12.<sup>2,4</sup> Older adults and individuals with gastrointestinal disorders like Crohn's disease or celiac disease are more likely to experience malabsorption issues, thereby increasing their risk of deficiency.<sup>3,5,6</sup> Furthermore, patients who have undergone total gastrectomy are at a particularly high risk of developing vitamin B12 deficiency.<sup>3,6</sup>

In this article, we present the case of severe vitamin B12 deficiency in a patient who underwent total gastrectomy and esophagectomy with ileum-right colon reconstruction and exhibited general weakness and rapidly progressing cognitive impairment.

## 2. Case report

An 80-year-old woman visited our clinic with a chief complaint of general weakness for 6 months. She also reported poor appetite and numbness in both hands. Notably, there was a rapid decline in cognitive function, including memory impairment and behavioral changes, such as attempting to shower while fully dressed. Her medical history included a total gastrectomy with ileum-right colon reconstruction due to attempted suicide involving pesticide ingestion 35 years ago, as well as a diagnosis of diabetes mellitus, which she managed with regular metformin therapy.

Though the patient had undergone total gastrectomy 35 years ago but her symptoms developed after she without regular methylcobalamin supplement and medical follow-up. She displayed significant weakness on general examination and was underweight, with a body mass index (BMI) of 17.3 kg/m<sup>2</sup> (height: 140 cm, body weight: 34 kg). Physical examination revealed pale conjunctiva and numbness in the distal portions of both hands. The neurological assessment showed symmetric muscle weakness in all four limbs, with intact light touch sensation in the fingers and feet. She also reported dysthermesthesia, experiencing foot pain when exposed to hot water. Hematological and biochemical investigations revealed several abnormalities, including macrocytic anemia (hemoglobin level: 6.9 g/dL, mean corpuscular volume [MCV]: 137.1 fL), leukopenia (4,100/uL), and thrombocytopenia (70,000/uL). Her vitamin B12 level was critically low at 0 pg/mL (measured with the Abbott Alinity I B12 Reagent Kit, 07P67). Both iron (26 ug/dL) and TIBC (197 ug/dL) level are low. The level of vitamin D is not available in our case. No signs of folate deficiency (18.01 ng/ml) or hypothyroidism were observed.

\* Corresponding author. Division of Gastroenterology, Department of Internal Medicine, MacKay Memorial Hospital, No. 92, Sec. 2, Chungshan North Road, Taipei, Taiwan.  
E-mail address: mingjen.ch@msa.hinet.net (M.-J. Chen)

Esophagogastroduodenoscopy revealed total gastrectomy status with an esophagus-ileum-colon-jejunum anastomosis (Figure 1).

Vitamin B12 deficiency-associated anemia was diagnosed, and she was subsequently treated with methylcobalamin, a form of vitamin B12, at a dose of 500 mcg intramuscular injections 8-hourly for 5 days. Full diet support designed by a dietitian was applied during the admission, and an oral form of methylcobalamin 500 mcg 12-hourly was also administered at the outpatient department. After 2 months, her vitamin B12 level had improved to over 2,000 pg/mL, pancytopenia had resolved, hemoglobin level, MCV, platelet count, and white blood cell count had increased to 11.4 g/dL, 95.1 fL, 225,000/uL, and 5,000/uL, respectively. Her symptoms, including general weakness, limb numbness, and cognitive function significantly improved.

3. Discussion

Human nutrition has significantly improved in modern society; however, vitamin B12 deficiency is still found in geriatrics and individuals with a history of total gastrectomy.<sup>3,5,6</sup> The prevalence of vitamin B12 deficiency is approximately 6% and 20% in individuals aged < 60 years and > 60 years, respectively.<sup>7</sup> A study by Asselt et al. found that older adults (average age of 76 years) with normal vitamin B12 markers had a median vitamin B12 intake of 6.3 µg/day from diet and supplements. Those with mild vitamin B12 deficiency had a median intake of 4.9 µg/day, and those with a possible deficiency had a median intake of 5.1 µg/day.<sup>8</sup> Once vitamin B12 is ingested, hydrochloric acid and the enzyme pepsin play a critical role in food digestion and releasing vitamin B12 from the attached proteins. Then, vitamin B12 binds to intrinsic factors produced by the parietal cells of the stomach. The intrinsic factor-vitamin B12 complex passes into the small intestine and is absorbed in the ileum. This absorption process is facilitated by receptors on the ileal mucosa, which bind to the vitamin B12-intrinsic factor complex, allowing its transportation into the systemic circulation.

Paying greater attention to older adults regarding vitamin B12 deficiency is essential. In the present case, the vitamin B12 deficiency can be attributed to older age and history of total gastrectomy and esophagectomy with ileum-right colon reconstruction. To-

tal gastrectomy significantly impacts vitamin B12 absorption due to the loss of intrinsic factors. Vitamin B12 deficiency prevalence of 48.8% has been reported in patients with gastric cancer who underwent gastrectomy.<sup>9</sup> For patients who underwent total gastrectomy, vitamin B12 deficiency was observed in 71.4% of cases, and enteral vitamin B12 supplements effectively improved anemia.<sup>10</sup> Park et al. reported that patients with upper-third early gastric cancer who received laparoscopic proximal gastrectomy with double-tract reconstruction required less vitamin B12 supplementation than those who received laparoscopic total gastrectomy.<sup>11</sup> It means that the fewer portions of gastrectomy, the lower the risk of vitamin B12 deficiency.

Battat et al. discovered that patients with inflammatory bowel disease who underwent ileal resections exceeding 30 cm experienced a decrease in mean vitamin B12 concentrations. Additionally, they observed a trend towards a higher proportion of individuals with vitamin B12 levels falling below the reference range but not increasing in the rates of vitamin B12 deficiency.<sup>12</sup> Our case underwent a total gastrectomy with ileum-right colon reconstruction, which has had a significant impact on her vitamin B12 absorption. This is due to a 'double-hit' effect resulting from the absence of the stomach, leading to the loss of intrinsic factors and the surgical reconstruction of the ileum-right colon, further reducing the absorption of vitamin B12. These 'double-hit' surgical procedures placed her at a marked risk of developing vitamin B12 deficiency.

The symptoms of vitamin B12 deficiency can manifest gradually and vary in severity. Early signs may include fatigue, weakness, and pale or jaundiced skin. Individuals may experience neurological

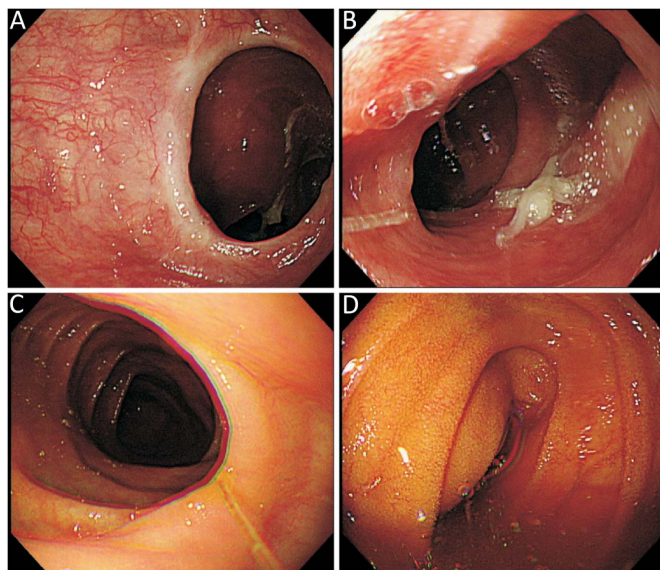


Figure 1. Esophagogastroduodenoscopy reveals the anastomosis site between the residual esophagus and the ileum (A). The initial reconstructed segment is the terminal ileum (B). The subsequent reconstructed segment is the ascending colon (C). Reconstructed segment is connected to the jejunum (D).

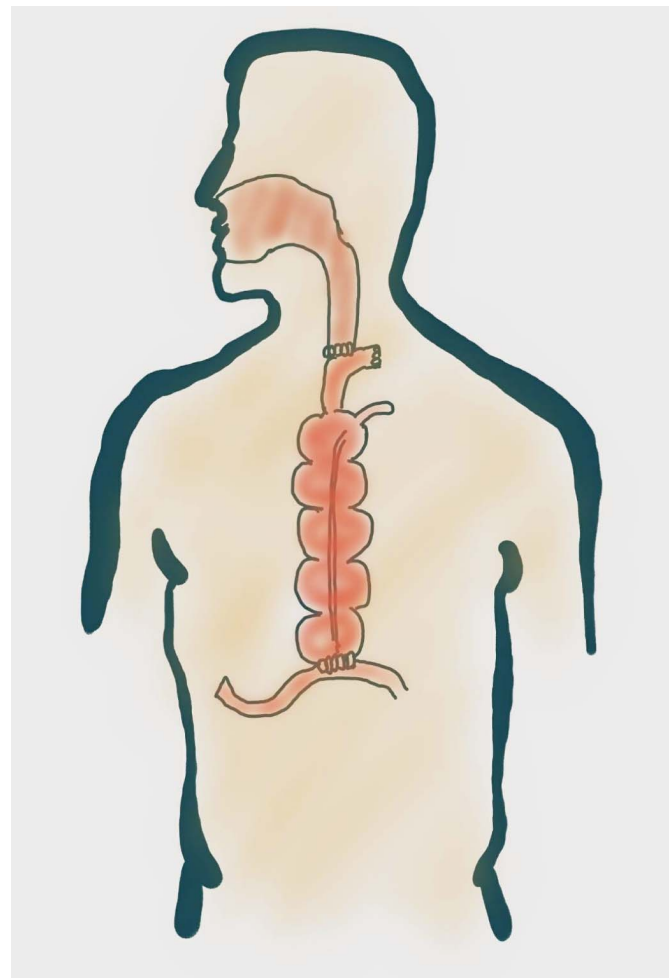


Figure 2. The drawing picture revealed the method of the reconstruction operation.

symptoms, such as numbness or tingling in the extremities, difficulty walking, and memory problems as the deficiency progresses.<sup>1,3</sup> Our case illustrated the symptoms that can occur when vitamin B12 levels are severely deficient. These symptoms include limb numbness, difficulty walking, memory problems, and pancytopenia development. When vitamin B12 levels are deficient, these symptoms can manifest; however, they can often be improved by administering vitamin B12 supplements. The treatment of vitamin B12 deficiency typically involves dietary supplementation and, in some cases, injections or nasal sprays. The most common and effective treatment for vitamin B12 deficiency is oral supplementation with cyanocobalamin or other vitamin B12 forms. This is often administered as daily or weekly doses, depending on the severity of the deficiency and the underlying cause.<sup>2,3</sup> In cases of severe vitamin B12 deficiency or absorption issues in the gastrointestinal tract, administering vitamin B12 via intramuscular injections is an effective way to improve vitamin B12 levels. These injections are typically given once a week for several weeks, followed by maintenance doses as needed.<sup>2,3</sup> Previous studies reveal that high-dose oral vitamin B12 supplementation and intramuscular administration of vitamin B12 are equally effective in treating vitamin B12 deficiency in patients undergoing gastrectomy.<sup>9,10,13</sup> The mechanism might be passive absorption of vitamin B12, although only 1–2% of vitamin B12 is generally absorbed in this way.<sup>14,15</sup> Subsequently, we initiated a combination of dietary supplementation and oral methylcobalamin for approximately one month. Her vitamin B12 level had improved to over 2,000 pg/mL. Oral methylcobalamin 500 mcg 12-hourly combine with diet supplement and education, we proven it is work as an alternative approach for the convenience. Nasal spray formulations of vitamin B12, such as hydroxocobalamin, may also be used as an alternative to injections, particularly for patients with difficulty with injections.

Vitamin B12 deficiency remains a prevalent concern, especially in older people and those who have undergone gastrectomy. These methods are equally effective in raising vitamin B12 levels in older adults.<sup>16,17</sup>

Vitamin D deficiency has been recognized as a potential contributor to anemia. The potential mechanisms are that vitamin D might down-regulating pro-inflammatory cytokines and hepcidin, may increase iron availability. The prevalence of vitamin D deficiency and iron deficiency are higher in the elderly. But the data of vitamin D is not available in our case.<sup>18</sup>

### Conflicts of interest statement

Authors declare no conflict of interests for this article.

### References

1. Stabler SP. Clinical practice. Vitamin B12 deficiency. *N Engl J Med*. 2013; 368(2):149–160. doi:10.1056/NEJMc1113996
2. Aroda VR, Edelstein SL, Goldberg RB, et al. Long-term metformin use and vitamin B12 deficiency in the diabetes prevention program outcomes study. *J Clin Endocrinol Metab*. 2016;101(4):1754–1761. doi:10.1210/jc.2015-3754
3. Oh R, Brown DL. Vitamin B12 deficiency. *Am Fam Physician*. 2003;67(5): 979–986.
4. Pawlak R, Lester SE, Babatunde T. The prevalence of cobalamin deficiency among vegetarians assessed by serum vitamin B12: a review of literature [published correction appears in *Eur J Clin Nutr*. 2016 Jul;70(7): 866]. *Eur J Clin Nutr*. 2014;68(5):541–548. doi:10.1038/ejcn.2014.46
5. Green R, Allen LH, Bjørke-Monsen AL, et al. Vitamin B<sub>12</sub> deficiency [published correction appears in *Nat Rev Dis Primers*. 2017 Jul 20;3:17054]. *Nat Rev Dis Primers*. 2017;3:17040. doi:10.1038/nrdp.2017.40
6. Guéant JL, Guéant-Rodriguez RM, Alpers DH. Vitamin B12 absorption and malabsorption. *Vitam Horm*. 2022;119:241–274. doi:10.1016/bs.vh.2022.01.016
7. Shipton MJ, Thachil J. Vitamin B12 deficiency - A 21st century perspective. *Clin Med (Lond)*. 2015;15(2):145–150. doi:10.7861/clinmedicine.15-2-145
8. van Asselt DZ, de Groot LC, van Staveren WA, et al. Role of cobalamin intake and atrophic gastritis in mild cobalamin deficiency in older Dutch subjects. *Am J Clin Nutr*. 1998;68(2):328–334. doi:10.1093/ajcn/68.2.328
9. Bahardoust M, Aghakhani Z, Mousavi S, et al. Vitamin B12 deficiency after total gastrectomy for gastric cancer, prevalence, and symptoms: a systematic review and meta-analysis. *Eur J Cancer Prev*. 2023. doi:10.1097/CEJ.0000000000000838
10. Namikawa T, Maeda M, Yokota K, et al. Enteral vitamin B12 supplementation is effective for improving anemia in patients who underwent total gastrectomy. *Oncology*. 2021;99(4):225–233. doi:10.1159/000513888
11. Park DJ, Han SU, Hyung WJ, et al. Effect of laparoscopic proximal gastrectomy with double-tract reconstruction vs total gastrectomy on hemoglobin level and vitamin B12 supplementation in upper-third early gastric cancer: A randomized clinical trial. *JAMA Netw Open*. 2023;6(2):e2256004. doi:10.1001/jamanetworkopen.2022.56004
12. Battat R, Kopylov U, Byer J, et al. Vitamin B12 deficiency in inflammatory bowel disease: a prospective observational pilot study. *Eur J Gastroenterol Hepatol*. 2017;29(12):1361–1367. doi:10.1097/MEG.00000000000000970
13. Hsu PI, Chuah SK, Lin JT, et al. Taiwan nutritional consensus on the nutrition management for gastric cancer patients receiving gastrectomy. *J Formos Med Assoc*. 2021;120(1 Pt 1):25–33. doi:10.1016/j.jfma.2019.11.014
14. Fedosov SN. Physiological and molecular aspects of cobalamin transport. *Subcell Biochem*. 2012;56:347–367. doi:10.1007/978-94-007-2199-9\_18
15. Jia CQ, Wang SY, Yuan Y, et al. The passive diffusion improvement of vitamin B<sub>12</sub> intestinal absorption by Gelucire that fit for commercialized production. *Saudi Pharm J*. 2023;31(6):962–971. doi:10.1016/j.jsps.2023.04.024
16. van Asselt DZ, Merkus FW, Russel FG, Hoefnagels WH. Nasal absorption of hydroxocobalamin in healthy elderly adults. *Br J Clin Pharmacol*. 1998; 45(1):83–86. doi:10.1046/j.1365-2125.1998.00642.x
17. Rozgony NR, Fang C, Kuczmarowski MF, Bob H. Vitamin B(12) deficiency is linked with long-term use of proton pump inhibitors in institutionalized older adults: could a cyanocobalamin nasal spray be beneficial? *J Nutr Elder*. 2010;29(1):87–99. doi:10.1080/01639360903574734
18. Smith EM, Tangpricha V. Vitamin D and anemia: insights into an emerging association. *Curr Opin Endocrinol Diabetes Obes*. 2015;22(6):432–438. doi:10.1097/MED.0000000000000199