



Medical Imagery

## Portomesenteric Venous Thrombosis Following Hepatectomy and Splenectomy

Che-Ming Yeh, Min-Po Ho \*

Department of Emergency Medicine, Far Eastern Memorial Hospital, New Taipei City, Taiwan

### ARTICLE INFO

Accepted 28 October 2021

A 65-year-old woman with a history of liver cirrhosis, and hepatocellular carcinoma was brought to emergency room for progressive abdominal pain for 2 days. She had undergone laparoscopic partial hepatectomy (2 cm at S4) and splenectomy 2 months ago. Physical examinations disclosed mild tenderness without peritoneal signs. Computed tomography (CT) of the abdomen demonstrated portomesenteric venous thrombosis (Figure 1A and B). She was managed with enoxaparin injection and discharged with stable condition.

Acute portomesenteric venous thrombosis is a rare but potentially life-threatening disease. The reported incidence rates of portal vein thrombosis (PVT) following hepatectomy and splenectomy was of 9.1% and 4.8%, respectively.<sup>1,2</sup> The overall mortality rate may be as high as 60%–80%, especially in patients whose diagnosis is delayed by > 24 hours after presentation.<sup>3</sup> The risks factors associated with PVT after hepatectomy include liver cirrhosis, intra-abdominal infection/inflammation, the duration of the Pringle maneuver during the operation, postoperative bile leakage, portal flow reduction, and splenectomy.<sup>4</sup> Splenectomy is also known to increase the risk of PVT because of hemodynamic alteration and a low-flow state in the splenoportal axis.<sup>5</sup> Patients may be asymptomatic or may present with unspecific abdominal pain. In some cases, PVT or mesenteric vein thrombosis (MVT) is incidentally found during abdominal imaging that was performed for other reasons. In contrast, patients with combined PVT/MVT may also suffer from severe abdominal pain, gastrointestinal bleeding, vomiting, and diarrhea. When the PVT extends to the mesenteric of splenic veins, an acute abdomen including signs of ischemia, and sepsis may occur.<sup>6</sup>

In conclusion, contrast-enhanced CT is the diagnostic modality of choice,<sup>4,6</sup> and treatment should be initiated soon after diagnostic confirmation. Anticoagulants are the first line of therapy if PVT/MVT

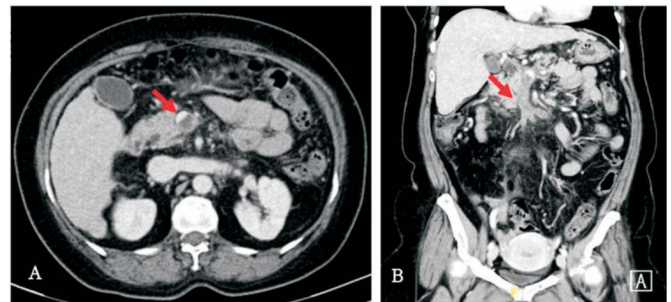


Figure 1. (A and B) Contrast-enhanced CT showing portomesenteric venous thrombosis (Red arrows).

is detected  $\geq 1$  week post-surgery; otherwise, emergent thrombectomy is recommended.<sup>6</sup>

### Funding sources and related paper presentations

None.

### References

1. Yoshiya S, Shirabe K, Nakagawara H, et al. Portal vein thrombosis after hepatectomy. *World J Surg.* 2014;38(6):1491–1497.
2. Stamou KM, Toutouzas KG, Kekis PB, et al. Prospective study of the incidence and risk factors of postsplenectomy thrombosis of the portal, mesenteric, and splenic veins. *Arch Surg.* 2006;141(7):663–669.
3. Berland T, Oldenburg WA. Acute mesenteric ischemia. *Curr Gastroenterol Rep.* 2008;10(3):341–346.
4. Kuboki S, Shimizu H, Ohtsuka M, et al. Incidence, risk factors, and management options for portal vein thrombosis after hepatectomy: a 14-year, single-center experience. *Am J Surg.* 2015;210(5):878–885.e2.
5. Ushitora Y, Tashiro H, Takahashi S, et al. Splenectomy in chronic hepatic disorders: portal vein thrombosis and improvement of liver function. *Dig Surg.* 2011;28(1):9–14.
6. Lang SA, Loss M, Wohlgemuth WA, et al. Clinical management of acute portal/mesenteric vein thrombosis. *Viszeralmedizin* 2014;30(6):394–400.

\* Corresponding author. Department of Emergency Medicine, Far Eastern Memorial Hospital, No. 21, Section 2, Nanya S. Rd., Banqiao Dist., New Taipei City 220, Taiwan.  
E-mail address: [hominpo@yahoo.com.tw](mailto:hominpo@yahoo.com.tw) (M.-P. Ho)