



Medical Imagery

A Hypopyon in an Elderly

I-Ming Lee^{a,b,c}, Ming-Jen Chen^{a,b,c}*

^a Division of Gastroenterology and Hepatology, Department of Internal Medicine, MacKay Memorial Hospital, Taipei, Taiwan, ^b MacKay Junior College of Medicine, Nursing and Management, Taipei, Taiwan, ^c MacKay Medical College, New Taipei City, Taiwan

ARTICLE INFO

Accepted 9 June 2021

A 69-year-old man with a history of diabetes mellitus reported having blurry vision in the left eye 2 days before hospital admission. Slit-lamp examination showed the presence of hypopyon (Figure 1A). This finding was suggestive of endogenous endophthalmitis. Abdominal CT was performed which revealed gallstones and a 3.5 × 2.8 cm abscess in segment 1 of the liver (Figure 1B). Blood and eye pus were positive for *Klebsiella pneumoniae*. The patient was treated with left eye pus aspiration and four intravitreal injections of vancomycin and ceftazidime for endophthalmitis. Ceftazidime plus metronidazole were administered for systemic treatment. Even with prompt and aggressive treatments, the patient eventually lost light perception in his left eye after 10 weeks.

Endogenous endophthalmitis is a bacteremia or fungemia infecting the eye, in which microorganisms seed the choroid and then infect the vitreous. Patients with endogenous endophthalmitis present acutely deteriorating vision and eye ache within hours to few days. The sources of bacteremia include abdominal abscess, urinary tract infection and use of an indwelling catheter. In Taiwan and other east Asian countries, *K. pneumoniae* associated liver abscess is believed to be a major cause of endogenous endophthalmitis. *K. pneumoniae* usually spreads hematogenously from an initial focus such as a liver abscess, resulting in metastatic infections in the lung, brain, or eyes, and gas gangrene¹ particularly in people with impaired host defenses, such as those with diabetes, alcoholism, malignancy and elderly. In a series of 120 patients with endogenous endophthalmitis, more than one third patients were over 60 years old.²

Endogenous endophthalmitis is a threatening eye condition with poor prognosis and needs emergency management with intravitreal and systemic antibiotics that can cross the blood-eye barrier. In a series of 75 patients treated between 2001 and 2012, only 41% eyes achieved a visual acuity of 20/200 or better.³ Endogenous endophthalmitis should be considered in patients with *K. pneumoniae* bacteremia and history of diabetes mellitus and elderly who complain of blurry vision.

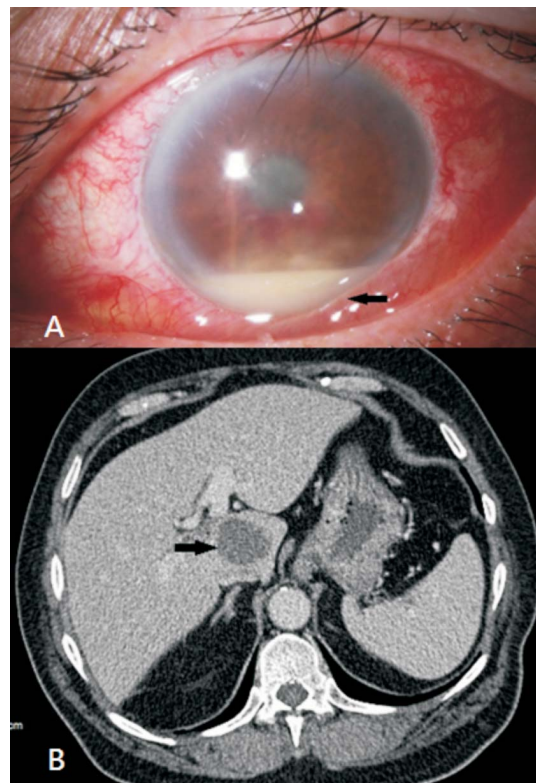


Figure 1. (A) Slit-lamp examination showing the presence of hypopyon, a collection of pus in the anterior chamber (arrow). (B) Abdominal CT showed a 3.5 × 2.8 cm, heterogeneous, low-density liver abscess in the S1 segment (arrow).

References

1. Chang CW, Wang TE, Shih SC, et al. Shortness of breath, fever and pain in both legs. *Lancet*. 2008;372:1518.
2. Muda R, Vayavari V, Subbiah D, et al. Endogenous endophthalmitis: a 9-year retrospective study at a tertiary referral hospital in Malaysia. *J Ophthalmic Inflamm Infect*. 2018;8:14.
3. Jackson TL, Paraskevopoulos T, Georgalas I. Systematic review of 342 cases of endogenous bacterial endophthalmitis. *Surv Ophthalmol*. 2014; 59:627–635.

* Corresponding author. Division of Gastroenterology and Hepatology, Department of Internal Medicine, MacKay Memorial Hospital, No. 92, Sec. 2, Chung-Shan North Road, Taipei, Taiwan.

E-mail address: mjgen.ch@msa.hinet.net (M.-J. Chen)