



Original Article

## Effects of Prosthetic Therapy in the Treatment of Edentulous Patients with Obstructive Sleep Apnea

Biljana Milosevic<sup>a\*</sup>, Ivica Stancic<sup>b</sup>, Ljiljana Tihacek Sojic<sup>b</sup>

<sup>a</sup> Medical Faculty, Dentistry Department, University of Montenegro, Podgorica, Montenegro, <sup>b</sup> Faculty of Dentistry, Prosthetic Department, University of Belgrade, Serbia

### ARTICLE INFO

Accepted 19 June 2019

#### Keywords:

apnea-hypopnea index,  
complete dentures,  
obstructive sleep apnea,  
vertical dimension of occlusion

### SUMMARY

**Background:** This study is based on the assumption that the reduced vertical dimension of occlusion (VDO) in patients wearing complete dentures could be one of the causes of OSA appearance. The aim of the study was to examine the effect of prosthetic treatment which corrects the reduced VDO in edentulous patients with OSA.

**Methods:** The study involved 20 edentulous patients with apnea/hypopnea index per hour of sleep (AHI/h)  $> 5.7 < 32.5$ . The methodology of research required a multidisciplinary chronological protocol from collection of anamnestic data, intraoral examination, polysomnographic (PSG) registration during sleep, and diagnosis by using the magnetic resonance imaging (MRI) to fabrication of the complete dentures in accordance with the established clinical procedures. Volume analysis (in cubic millimeters) of the pharynx was performed as sum of the segmented areas multiplied by their thickness.

**Results:** Prosthetic therapy in edentulous patients with OSA reduced the value of AHI/h. The average value of AHI/h based on the sample data before the treatment was  $17.6 \pm 8.9$  while three months after the treatment with complete dentures AHI/h amounted to  $9.7 \pm 6.5$  ( $p < 0.001$ ). After three months from prosthetic rehabilitation, MRI showed a mean volume increase of 27% of pharynx in edentulous patients with OSA.

**Conclusion:** The prosthetic treatment with complete dentures which corrects VDO provides adequate support to orofacial structures, increases the volume of the pharynx and reduces the symptoms of OSA in edentulous patients.

Copyright © 2019, Taiwan Society of Geriatric Emergency & Critical Care Medicine.

## 1. Introduction

In modern literature, there are few data regarding the prevalence of obstructive sleep apnea (OSA) in edentulous patients as well as the treatment possibilities.<sup>1–4</sup> Additionally, there are a small number of efficient evidence-based treatment strategies, which indicate a further need for clinical research.<sup>5</sup>

Many authors suggest that edentulism leads to the changes in the vertical dimension of occlusion (VDO), which further causes morphological changes in upper airways, reduction of retropharyngeal space and the tone of pharyngeal muscles.<sup>6</sup>

Loss of the VDO and reduction of the lower third of the face in edentulous patients can affect the size and function of the upper airways.<sup>6</sup> The role of VDO in OSA pathogenesis is still being researched.<sup>4</sup> Moreover, it was noticed that extractions of all teeth affect the cardio respiratory state of patients and lead to increased numbers of apnea or hypopnea episodes per hour of sleep (AHI/h).<sup>7</sup>

OSA symptoms in edentulous patients who did not wear complete dentures or wore inadequate abraded dentures lead to the assumption that the reduced VDO may be one of the causes of

incidence of OSA. The reduced VDO in edentulous patients change the position of mandibulae, tongue, pharynx, and therefore, it reduces the flow in the upper airways.<sup>6–8</sup>

Accordingly, this study started from the hypothesis that the reconstruction of optimal vertical dimension of occlusion with complete dentures would reduce the symptoms of OSA i.e. the value of AHI/h in edentulous patients.

The aim of this study was to determine the effects of the prosthetic therapy with the complete dentures in edentulous patients with OSA.

## 2. Patients and Methods

Prior to starting the research, a positive opinion was obtained from the Ethics Committee of the Clinical Center of Montenegro (central Ethics Committee), decision number 03/01-12120/1.

This prospective study included 20 edentulous patients, with OSA symptoms who were prosthetically rehabilitated at the Stomatology Clinic, Clinical Centre of Montenegro.

The criteria for the selection of the patients in this study were: the state of complete edentulism, the patients with old complete dentures and reduced VDO, patients' age and AHI/h  $> 5$  (Figure 1).

A special questionnaire designed by the researchers was used to collect anamnestic data. The questionnaire enabled the deter-

\* Corresponding author. Medical Faculty – Dentistry Department, University of Montenegro, 81 000 Podgorica, Montenegro.

E-mail address: [biljana.m13@gmail.com](mailto:biljana.m13@gmail.com) (B. Milosevic)

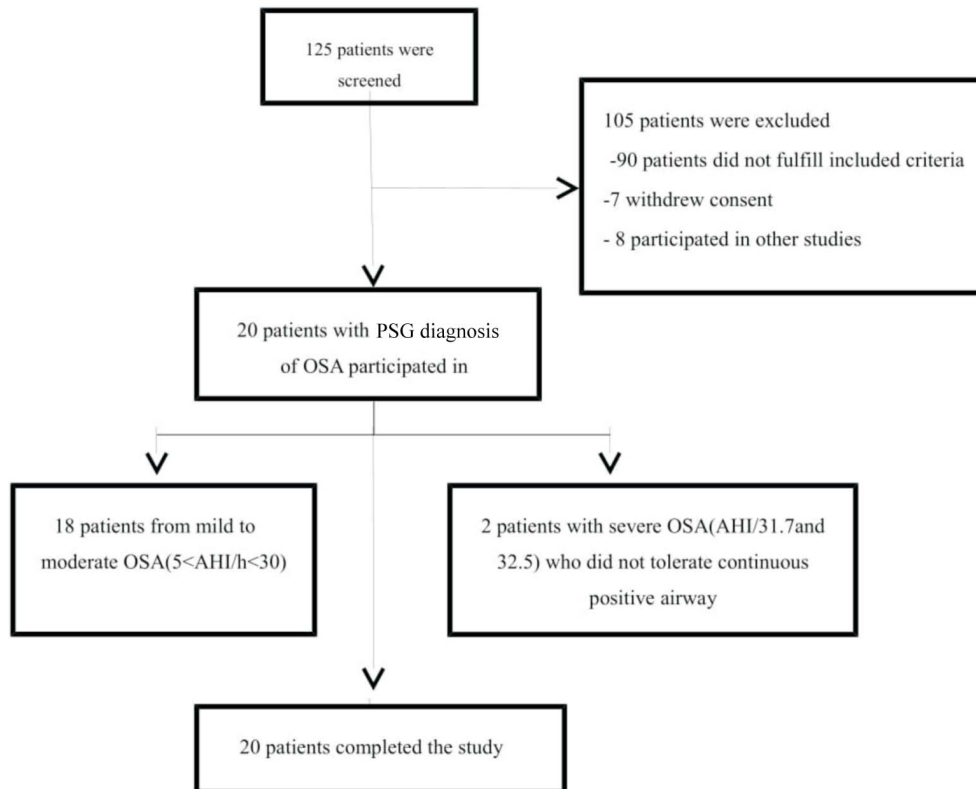


Figure 1. Chart flow of the selection of patients.

mination of the continuity of sleep, position of body during sleep, the incidence of snoring, as well as subjective sensations of patients such as morning fatigue, headaches, problems with concentration and drowsiness during the day. This questionnaire included the data regarding the loss of natural teeth, length of existing denture wearing as well as the characteristics of the existing dentures. The following questions of crucial importance for edentulous patients with OSA are: Q<sub>1</sub> – When did you have your last extraction? Q<sub>2</sub> – How long have you been wearing complete dentures? Q<sub>3</sub> – Do you sleep with complete dentures? Q<sub>4</sub> – When did you notice your first breathing interruptions during sleep? Q<sub>5</sub> – How frequently do you wake up during night?

The questionnaire was designed in accordance to the STOP Questionnaire for Obstructive Sleep Apnea<sup>9</sup> and The Berlin questionnaire (BQ).<sup>10</sup>

The Epworth Sleepiness Scale (ESS) was applied to assess each patient's sleep with the following characteristics: bad, good, very good or excellent. The questionnaire included the body mass index (BMI) and eight questions related to drowsiness.<sup>11</sup>

The clinical examination performed for each patient involved following analysis: VDO, functionality of the existing dentures, skeletal intermaxillary jaw structures according to the Steiner,<sup>12</sup> morphological characteristics of soft oral tissues according to Mallampati score.<sup>13,14</sup>

Bearing in mind the recent research results according to the Mallampati score, two patients with severe forms of OSA did not undergo this analysis.<sup>15</sup>

The polysomnographic (PSG) registration was performed in the sleep-laboratory of the hospital for lung diseases and tuberculosis "Dr Jovan Bulajic" in Niksic, Montenegro in the device Alice Night One (Philips Respironics company, Murrysville, Pennsylvania, USA). The registration was performed during sleep in duration from 440 to 450 min. PSG was performed in all patients before treatment with

existing complete dentures (old, abraded) and three months after prosthetic rehabilitation with the new complete dentures. The acquired graphical and numerical polysomnogram was analyzed in the G3 – Philips program (Sleepware G3 sleep diagnostic software) and included the following parameters:

- AHI/h;
- AHI/h on the side;
- AHI/h on the back;
- the mean values of apneic/hypopneic episodes duration in seconds;
- the maximum values of apneic/hypopneic episodes duration in seconds;
- snoring index;
- the cardiac frequency (beats per minute-n/bpm).

In accordance with the instructions of on American Academy of sleep Medicine (AASM) the authors carried out the data scoring about the sleep before and after the prosthetic rehabilitation of edentulous patients with OSA.<sup>16</sup>

All patients (20) accepted to undergo MRI before and after the prosthetic rehabilitation at the Clinical Center of Montenegro. The examinations were performed on the device for magnetic resonance imaging (Siemens), with magnetic field strength of 1.5 Tesla, in the T1 sequence in inspirium (T<sub>1</sub> sagittal, T<sub>1</sub> axial and T<sub>1</sub> coronary tomographs).

The segmentation of pharynx was performed in MedInria (Centre de recherche Inria, Le Chesnay Cedex, France)<sup>17</sup> software using "magic wand" and "paint/erase" segmentation tools. The segmented image was saved and then opened in MIPAV (Medical Image Processing and Visualization, NIH, Bethesda, USA).<sup>18</sup> Using "Paint to VOI" tool, volume of interest (VOI) that encompasses the whole pharynx was defined and its volume was determined. Volume analysis (in cubic millimeters) of the pharynx was performed in MIPAV as the sum of the segmented areas multiplied by their thickness.<sup>18</sup>

The prosthetic rehabilitation by complete dentures was performed at the Dental Medicine Clinic of the Faculty of Medicine in Podgorica. For the purpose of this research, complete dentures in the upper and lower jaw were made for each patient (20 upper and 20 lower acrylic complete dentures).

The review examinations of the patients were carried out in the first, second and third month after the prosthetic treatment. The patients completed again the questionnaires mentioned before.

Statistical data analysis was performed using IBM SPSS Statistics 22 (IBM Corporation, Armonk, NY, USA). The data are shown in tabularized format by the arithmetic mean and standard deviations. For comparing the data obtained from the sample survey before and after the therapy, the student T-test was used. For each analysis, the level of statistical significance of the differences between the tested parameters is given. All p-values less than 0.05 were considered significant.

### 3. Results

The average age of patients was  $66.7 \pm 6.4$ , of those 7 (35%) were male and 13 (65%) female. BMI ranged from 22, 39 to 37, 34  $\text{kg}/\text{m}^2$ . One patient had normal body weight, seven patients were overweighted ( $25\text{--}29$ ,  $9 \text{ kg}/\text{m}^2$ ), two patients had class I obesity ( $30\text{--}34$ ,  $9 \text{ kg}/\text{m}^2$ ) and one patient had class II obesity.

The results obtained from the questionnaire before the prosthetic treatment indicated that 87.5% of patients suffered from sleep disorders, while snoring and morning fatigue were present in 100% of the patients. Furthermore, 100% of the patients suffered from drowsiness during the day and had problems with concentration, while 50% of the patients had headaches during the day. In all of these patients, symptoms of OSA appeared after loss of teeth.

The intraoral examination in patients with existing dentures showed that the size of the tongue was confined within the tongue space. In patients who did not wear dentures for a longer period (2 years), the size of the tongue showed an increase, sometimes spreading over the residual ridge. According to the Mallampati classification, 75% of respondents were classified into II or III class. Also, the extremely sloping position of the soft palate in the position of rest and low positioning of the uvula were identified in 75% of the patients, the increased uvula was identified in 45% and hypertrophic tonsillas were identified in 25% of the patients.

The analysis of the skeletal intermaxillary relations showed the first skeletal class in 13 patients, the second skeletal class in 6 patients and the third skeletal class in 1 patient.

The PSG testing showed that the AHI/h before the prosthetic rehabilitation with complete dentures ranged from 5.70 to 32.5, while it ranged from 1.6 to 24.1 after the treatment. The average value of AHI/h before the treatment was  $17.6 \pm 8.9$ . Three months after the treatment with complete dentures AHI/h was  $9.7 \pm 6.5$  i.e. it fell by 48.8% compared to the index values before the prosthetic treatment ( $p < 0.001$ ) (Table 1).

The average value of AHI/h during the sleep on the back was  $24.3 \pm 21.4$  before the prosthetic treatment, while after the prosthetic rehabilitation the index reduced to  $10.4 \pm 7.3$ . The treatment with complete dentures significantly reduced AHI/h on the back by 41.9% ( $p = 0.006$ ) (Table 1).

During the sleep on the side, the average value of AHI/h before the treatment was  $14.2 \pm 16.9$  while it was  $6.2 \pm 6.6$  after the treatment with complete dentures, thus indicating significant decrease by 44.7% ( $p = 0.038$ ) (Table 1).

The PSG registration before and after the treatment showed that the prosthetic rehabilitation with complete dentures reduced the average duration of apneic/hypopneic crises by 22.91%, and maximum duration by 38.69% (Table 1).

The PSG registration affirmed that the mean duration of apnea/hypopnea crisis before the prosthetic therapy was in total  $19.6 \pm 4.4$  and after the therapy  $16 \pm 3.5$ . Maximum duration of apneic/hypopneic episodes before therapy was in total  $44.3 \pm 18.7$  and after the reconstruction VDO with complete dentures  $28.5 \pm 12.4$  ( $p < 0.001$ ) (Table 1).

The average value of snoring index before the treatment was  $164.7 \pm 160.7$  and after the treatment was  $59.7 \pm 62.2$ , which was significantly reduced by 65% ( $p = 0.002$ ) (Table 1).

The heart rate before the prosthetic rehabilitation during apneic/hypopneic episodes totaled  $116.7 \pm 26.5$ , and after the treatment  $91.7 \pm 14.3$  ( $p < 0.001$ ) (Table 1).

After the prosthetic treatment of the patients, day and night-time symptoms correlated with reduced AHI/h, which was reflected in the quality of sleep.

The results of the PSG examinations (AHI/h) proved the validity of the questionnaire (Table 1).

The results obtained from the conducted questionnaire and clinical examination clearly pointed that edentulism and reduced VDO had a direct impact on the appearance of OSA symptoms, which was also confirmed with PSG record AHI/h (Table 1).

The volumetric analysis of pharynx showed that the arithmetic mean and the standard deviation of the volume before the therapy was  $12,766 \pm 1,085 \text{ mm}^3$  while after the therapy it was  $16,151 \pm 1,542 \text{ mm}^3$  which is a statistically significant difference ( $p < 0.001$ ). There has been a significant increase in volume (Table 2, Figures 2, 3).

The average increase in pharynx was 27.0%. Minimum increase was 5.2% and maximum 51.8% (Figure 4).

### 4. Discussion

This study, in the prosthetic aspect, investigated the possibility of treating edentulous patients with OSA fabricating complete dentures with acceptable VDO.

Present investigation deals with the analysis of AHI/h, as well as of the volumetric analysis of pharynx before and three months after the prosthetic treatment of edentulous patients with OSA.

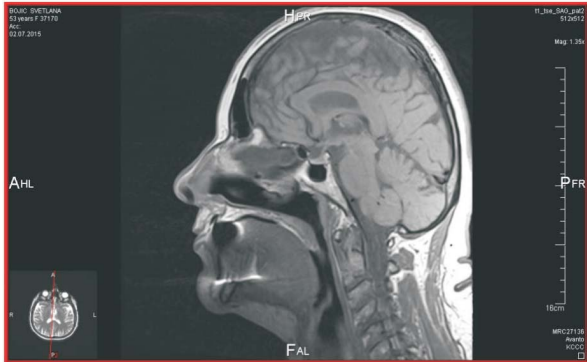**Table 1**  
PSG parameters before and after the prosthetic treatment in all patients (N = 20).

Parameters	Before the therapy -without dentures	After the therapy -with dentures	Mean improvement (%)	p-value
AHI/h	$17.6 \pm 8.9$	$9.7 \pm 6.5$	48.8	< 0.001
AHI/h on the back	$24.3 \pm 21.4$	$10.4 \pm 7.3$	41.9	0.006
AHI/h on the side	$14.2 \pm 16.9$	$6.2 \pm 6.6$	44.7	0.038
Mean duration (sec)	$19.6 \pm 4.4$	$16.0 \pm 3.5$	17.6	< 0.001
Max duration (sec)	$44.3 \pm 18.7$	$28.5 \pm 12.4$	33.9	< 0.001
Snoring index/h	$164.7 \pm 160.7$	$59.7 \pm 62.2$	65.0	0.002
Cardiac frequency (n/bpm)	$116.7 \pm 26.5$	$91.7 \pm 14.3$	19.3	< 0.001

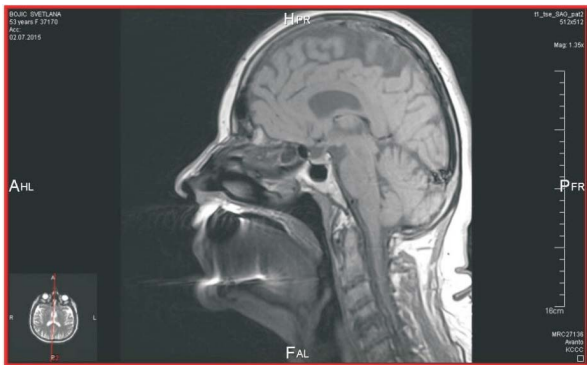**Table 2**  
Volumetric analysis of pharynx before and after prosthetic therapy.

Volume (mm <sup>3</sup> )	Mean	SD	Med	Min	Max	p-value
Before	12,766	1,085	12,801	11,396	14,439	p < 0.001
After	16,151	1,542	16,626	11,992	17,968	

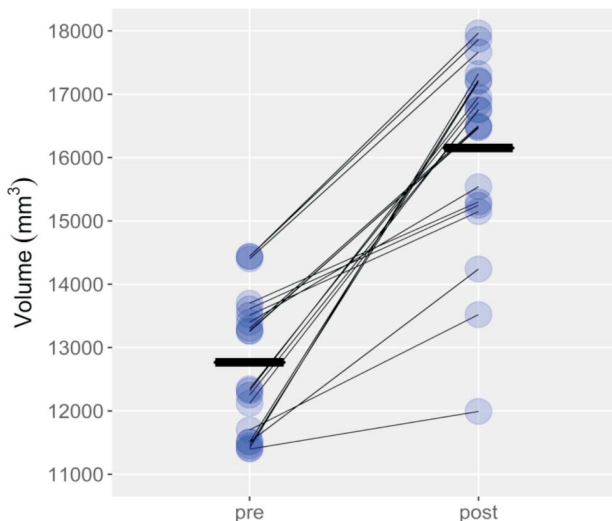
\* p-value refers to Mean (arithmetic mean).



**Figure 2.** MRI - Volume of the pharynx before therapy.



**Figure 3.** MRI - Volume of the pharynx after therapy.



**Figure 4.** Graphical presentation of the volume of pharynx before and after therapy.

Many studies have confirmed that the lowered soft palate, increased uvula and tongue hypertrophy are predisposing factors for the occurrence of sleep apnea.<sup>19</sup> The above predisposing factors and reduced VDO lead to significant obstruction of upper airways in edentulous patients, which turned to be true during this research, as well.

Our results had clearly shown that OSA symptoms appeared in

edentulous patients after loss of their natural teeth, and as a consequence of wearing inadequate, abraded complete dentures with the reduced VDO. Loss of teeth with lost or decreased VDO changed the position of the mandible, tongue and soft palate with very low positioning of the uvula, which leads to the reduced passage of the upper respiratory tract and the appearance of symptoms of OSA.

In all patients who had not been prosthetically rehabilitated for a longer period (1.3 years in average), tongue hypertrophy was detected, which was accompanied with edentulism and a low positioned uvula.

A significant decrease of VDO in these patients is the result of tooth loss, reduction of alveolar ridges and reduction in the physiological length of orofacial muscles which lost a natural support. i.e. the accommodation of the surrounding soft structures to the state of edentulism.

In those patients who used the existing dentures for 15.6 years on average, before the prosthetic treatment, it could be assumed that the reduced VDO is a consequence of reduction of residual alveolar ridges as well as of occlusal surfaces attrition of the artificial teeth.

The studies which researched the role of complete dentures in the reduction of AHI/h indicate that edentulism resulted in the reduction of the pharynx, which is a key risk factor for the incidence of OSA.<sup>1,4</sup> These studies showed that wearing complete dentures causes the increase in the retropharyngeal space in the lying position in edentulous patients with OSA and reduction in incidence of apneic-hypopneic episodes. The increase in the retropharyngeal space is a result of acceptable VDO during the fabrication of complete dentures.<sup>1,4</sup> Gupta et al. based their research on the assumption that the increased VDO by 2–3 mm may result in the increased retropharyngeal space.<sup>6</sup>

In this study, during the fabrication of new complete dentures, all patients underwent the reconstruction of VDO. The difference in VDO before and after the treatment at the level of sample was in total 3.2 mm. Taking into account the resorption of the alveolar ridge and the abrasion of acrylate teeth during wearing complete dentures, it is necessary to fabricate new complete dentures after five years.

Bucca et al. compared the PSG results of edentulous patients while sleeping with and without dentures.<sup>4</sup> The research showed that the AHI/h was significantly higher in the edentulous patients who slept without dentures than in those patients who slept with them.<sup>4</sup> This has been confirmed by Okşayan et al.<sup>20</sup> Furthermore, Arisaka et al. indicate that wearing complete dentures during sleep reduces AHI/h in the majority of edentulous patients.<sup>1</sup> Our results correlate with results of these authors because our edentulous patients were subject to PSG while wearing dentures and without wearing them, with reduction of AHI/h by 48.8% and snoring index by 65.0%.

This research showed that the adequate reconstruction of VDO by complete dentures reduced medium and maximum duration of A+H/h in seconds, AHI/h in different positions during sleep (sleeping on the back and sleeping on the side) and snoring index in edentulous patients with OSA. The treatment with complete dentures significantly reduces AHI/h as compared to the period before the prosthetic treatment (p < 0.001).

According to the definition, as the most stringent criterion for the success of treatment in patients with OSA, is considered the reduction of respiratory problems at < 5 per hour of sleep.<sup>21</sup> This investigation showed that the application of prosthetic rehabilitation in six patients (33%) reduced the value of AHI/h to < 5 (AHI/h = 4.3, 2.4, 1.6, 3.4, 1.6 and 2.7) and thus eliminated OSA and ac-

companying day and night time symptoms. The studies which used mandibular advancement devices in the treatment of mild and moderate forms of OSA also confirm the success of the applied treatment in reducing AHI/h.<sup>22–24</sup>

Emami et al. have found that the effects of prosthetic rehabilitation in edentulous patients with moderate and severe sleep apnea may have a preventive approach to the improvement of sleep characteristics in the older population and their quality of life.<sup>2</sup>

The cephalometric analysis of Erovigni et al. shows that wearing complete dentures changes the position of tongue, jaw and esophagus, which causes the reduction of apneic episodes.<sup>3</sup> Spirometry tests by Bucca et al. point to the significant reduction of the air-flow through upper airways in edentulous patients.<sup>25</sup>

Our study, in addition to PSG, used the MRI diagnosis in all patients (20) and showed a significant increase of the volume of the pharynx after the prosthetic treatment with complete dentures which correct VDO.

Gupta et al. applied lateral cephalometry and spotted significant increase of retropharyngeal space in patients who wore complete dentures with acceptable VDO in comparison to edentulous patients without dentures. These changes were more significant in the same patients after increasing VDO by 2 mm using custom made acrylic jig in comparison to edentulous patients.<sup>26</sup>

After maxillomandibular advancement (the most effective surgical treatment of OSA), MRI showed a mean volumetric increase of 26.72 % in the retropalatal region and of 27.2 % in the retrolingual region.<sup>27</sup>

In our study, MRI showed a significant mean increase of the pharynx of 27%, which is in accordance with the results of the previously mentioned studies.<sup>26,27</sup>

## 5. Conclusions

The prosthetic treatment with complete dentures which normalizes VDO in edentulous patients with OSA is an efficient and non-invasive method of treatment. Besides the rehabilitation of the basic functions of orofacial system, this therapy normalizes soft palate muscles and pharynx functions, which increases upper airways flow and reduces OSA symptoms.

## Acknowledgements

No.

## Funding/support statement

No.

## Competing interests

The authors declares that they have no competing interests.

## References

1. Arisaka H, Sakuraba S, Tamaki K, et al. Effects of wearing complete dentures during sleep on the apnea-hypopnea index. *Int J Prosthodont.* 2009;22(2):173–177.
2. Emami E, Salah MH, Rompre P, et al. The nocturnal use of complete dentures and sleep stability in edentulous elders. *J Dent.* 2013;41(8):703–709.
3. Erovigni F, Graziano A, Ceruti P, et al. Cephalometric evaluation of the upper airway in patients with complete dentures. *Minerva Stomatol.* 2005;54(5):293–301.
4. Bucca C, Cicolin A, Brussino L, et al. Tooth loss and obstructive sleep apnoea. *Respir Res.* 2006;17:8.
5. Heidsieck DS, de Ruyter MH, de Lange J. Management of obstructive sleep apnea in edentulous patients: An overview of the literature. *Sleep Breath.* 2016;20(1):395–404.
6. Gupta P, Thombare R, Pakhan AJ, et al. Cephalometric evaluation of the effect of complete dentures on retropharyngeal space and its effect on spirometric values in altered vertical dimension. *ISRN Dent.* 2011;2011:516969.
7. Bucca C, Carossa S, Pivetti S, et al. Edentulism and worsening of obstructive sleep apnoea. *Lancet.* 1999;353(9147):121–122.
8. Douglass JB, Meader L, Kaplan A, et al. Cephalometric evaluation of the changes in patients wearing complete dentures: A 20-year study. *J Prosthet Dent.* 1993;69(3):270–275.
9. Chung F, Yegneswaran B, Liao P, et al. STOP questionnaire: A tool to screen patients for obstructive sleep apnea. *Anesthesiology.* 2008;108(5):812–821.
10. Khaledi-Paveh B, Khazaie H, Nasouri M, et al. Evaluation of Berlin questionnaire validity for sleep apnea risk in sleep clinic populations. *Basic Clin Neurosci.* 2016;7(1):43–48.
11. Johns MW. A new method for measuring daytime sleepiness: The Epworth sleepiness scale. *Sleep.* 1991;14(6):540–545.
12. Steiner CC. Cephalometrics for you and me. *Am J Orthod.* 1953;39(10):729–755.
13. Hiremath AS, Hillman DR, James AL, et al. Relationship between difficult tracheal intubation and obstructive sleep apnoea. *Br J Anaesth.* 1998;80(5):606–611.
14. Liistro G, Rombaux P, Belge C, et al. High Mallampati score and nasal obstruction are associated risk factors for obstructive sleep apnoea. *Eur Respir J.* 2003;21(2):248–252.
15. Hukins C. Mallampati class is not useful in the clinical assessment of sleep clinic patients. *J Clin Sleep Med.* 2010;6(6):545–549.
16. Kapur VK, Auckley DH, Chowdhuri S, et al. Clinical practice guideline for diagnostic testing for adult obstructive sleep apnea: An American Academy of Sleep Medicine Clinical Practice Guideline. *J Clin Sleep Med.* 2017;13(3):479–504.
17. Toussaint N, Souplet JC, Fillard P. MedINRIA: Medical image navigation and research tool by INRIA. In *Proc. of MICCAI'07 Workshop on Interaction in Medical Image Analysis and Visualization.* Brisbane, Australia; 2007.
18. McAuliffe MJ, Lalonde FM, McGarry D, et al. Medical image processing, analysis and visualization in clinical research. *Proceedings 14th IEEE Symposium on Computer-Based Medical Systems. CBMS 2001.* Bethesda, MD, USA; 2001: 381–386.
19. Young T, Skatrud J, Peppard PE. Risk factors for obstructive sleep apnea in adults. *JAMA.* 2004;291(16):2013–2016.
20. Okşayan R, Sökücü O, Uyar M, et al. Effects of edentulism in obstructive sleep apnea syndrome. *Niger J Clin Pract.* 2015;18(4):502–505.
21. Thorpy MJ. Classification of sleep disorders. *Neurotherapeutics.* 2012;9(4):687–701.
22. Gotsopoulos H, Chen C, Qian J, et al. Oral appliance therapy improves symptoms in obstructive sleep apnoea: A randomized controlled trial. *Am J Respir Crit Care Med.* 2002;166(5):743–748.
23. Mehta A, Qian J, Petocz P, et al. Randomized, controlled study of a mandibular advancement splint for obstructive sleep apnea. *Am J Respir Crit Care Med.* 2001;163(6):1457–1461.
24. Rose E, Staats R, Virchow C, et al. A comparative study of two mandibular advancement appliances for the treatment of obstructive sleep apnoea. *Eur J Orthod.* 2002;24(2):191–198.
25. Bucca C, Carossa S, Colagrande P, et al. Effect of edentulism on spirometric tests. *Am J Respir Crit Care Med.* 2001;163(4):1018–1020.
26. Gupta P, Thombare R, Singhal S, et al. Obstructive sleep apnea and edentulism-role of complete dentures/oral appliance from prosthodontic perspective: A review. *Indian J Sleep Med.* 2010;5(4):116–119.
27. Faria AC, da Silva-Junior SN, Garcia LV, et al. Volumetric analysis of the pharynx in patients with obstructive sleep apnea (OSA) treated with maxillomandibular advancement (MMA). *Sleep Breath.* 2013;17(1):395–401.